

Utilizing Endoform as a Surrogate Marker of Wound Protease Levels in Chronic Wounds

Reginald Casilang, NP; and Simone Morissette, MSN, NP-C, WCC, CareMore Health Systems, Cerritos, California

Wound protease concentrations have long been recognized to correlate with inflammation and wound chronicity.^{1,2} The importance of wound proteases in dictating long-term healing outcomes has spurred the desire for simple, cost-effective, and readily available tools health care professionals can use to gauge wound protease concentrations.³

Endoform (Aroa Biosurgery Limited, Auckland, New Zealand) is an advanced intact extracellular matrix (ECM) with the same composition and function as tissue ECM. Clinical observations from Champion and Bohn⁴ described how Endoform changed in the wound bed over time among different wound types. One of their key obser-

variations was that when used in a highly proteolytic wound, Endoform degraded entirely in a day or 2 with little residual product in the wound bed at the time of reapplication. These authors⁴ also observed the rate of Endoform degradation slowed as inflammation resolved and the wound transitioned from the inflammatory phase (high protease concentrations) to the proliferative/remodeling phases (low protease concentrations).

We and others⁵ have implemented the early and aggressive management of wounds with Endoform to address protease imbalance and build tissue. We use this product as a clinical cue for elevated wound proteases. By starting

wound management with a defined amount of Endoform (2 layers) then observing the amount of residual ECM at days 3 and 7, we can judge the level of proteases and phase of healing at each reapplication and adapt our strategy accordingly to individualize each patient's wound management (see Figure). Therefore, Endoform serves as surrogate marker for the level of wound proteases present in a wound. Reconstituted collagen dressings immediately gel in the wound and therefore do not have this unique feature.⁶

We recently undertook a controlled case series (N = 20) to assess changes in Endoform following application. Our results,⁷ presented at the Symposium on

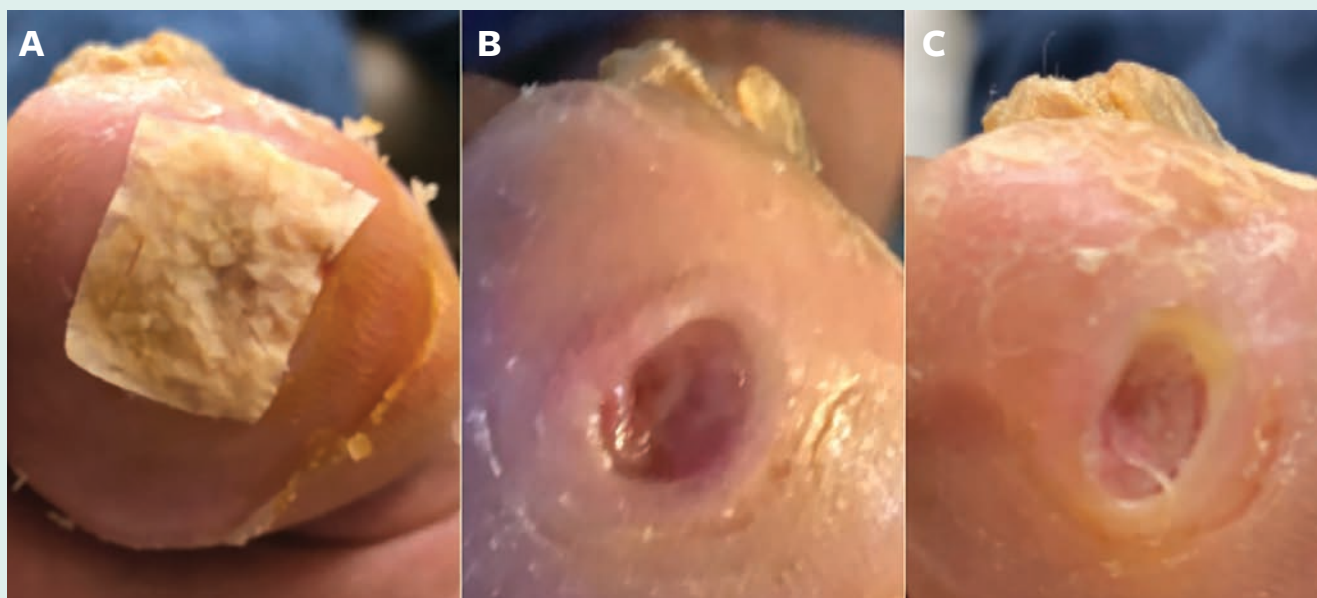


FIGURE. Wound management and assessment using Endoform: A) initial application of Endoform; B) day 3: high protease concentrations with only trace amounts of extracellular matrix (ECM) remaining; C) day 7: high protease concentrations. The ECM is entirely degraded.

Advanced Wound Care (SAWC Spring) 2019 in San Antonio, Texas, illustrate the real-world use of Endoform as a surrogate marker for wound protease levels. In this study, a variety of wounds, including diabetic foot ulcers and venous leg ulcers, were debrided then treated with Endoform on days 3 and 7. The amount of residual Endoform was assessed by the clinical team. High wound protease concentrations and subsequently wound chronicity were inversely proportional to the amount of residual Endoform.

For us and our practice, using Endoform has many benefits and primarily allows us to identify wounds with elevated proteases and monitor changes in wound proteases and, as such, monitor wound progression from the inflammatory phase into the proliferative phase and the building of new tissue. ■

REFERENCES

1. Lobmann R, Ambrosch A, Schultz G, Waldmann K, Schiweck S, Lehnert H. Expression of matrix-metalloproteinases and their inhibitors in the wounds of diabetic and non-diabetic patients. *Diabetologia*. 2002;45(7):1011-1016.
2. Schultz GS, Davidson JM, Kirsner RS, Bornstein P, Herman IM. Dynamic reciprocity in the wound microenvironment. *Wound Repair Regen*. 2011;19(2):134-148.
3. Snyder RJ, Driver V, Fife CE, Lantis J, Peirce B, Serena T, Weir D. Using a diagnostic tool to identify elevated protease activity levels in chronic and stalled wounds: a consensus panel discussion. *Ostomy Wound Manage*. 2011;57(12):36-46.
4. Champion S, Bohn G. Dressing appearance at change can give insight into dressing effectiveness in the wound. Presented at: the Clinical Symposium on Advances in Skin & Wound Care; September 18-21, 2015; New Orleans, Louisiana.
5. Bohn GA, Schultz GS, Liden BA, et al. Proactive and early aggressive wound management: a shift in strategy developed by a consensus panel examining the current science, prevention, and management of acute and chronic wounds. *Wounds*. 2017;29(11):S37-S42.
6. Gibson MC, Cullen B. Can natural materials be adapted to optimize their efficacy in wound care? Presented at: the Symposium for Advanced Wound Care Fall; October 16-18, 2014; Las Vegas, Nevada.
7. Morrisette S, Casilang R, Bohn GA. Extracellular matrix technology for assessing wound protease concentration. Presented at: the Symposium on Advanced Wound Care; May 7-11, 2019; San Antonio, Texas.



WOUND MANAGEMENT & PREVENTION

Determining Risk Factors to Develop a Predictive Model of Incontinence-associated Dermatitis Among Critically Ill Patients with Fecal Incontinence: A Prospective, Quantitative Study
Li Wei, BS, NRP, Yuh-jing Bao, MD, RN, Chuanwei Chai, MD, RN, Jing Zhang, MD, RN, and Sherven Xu, MD, RN

Quality of Life in Individuals With Peripheral Arterial Disease Who Underwent Toe Amputations: A Descriptive, Cross-sectional Study
Catherine R. Rouse, PhD, GNP-BC, CWOCN, CICM, David Strake, DNP, ACNP-BC, and Virginia Koenig, PhD

Implementation of a Competency-based Pressure Ulcer Curriculum for Medical Students: Outcomes from an Educational Intervention Study
Merla Hendrika van Zuijlen, PhD, AGSF, Preretha Kamath, BS, Juan Carlos Palacios, MD, and Marco Rotta Soares, MD

April 2019, Vol. 65, Issue 4

AN HMP PUBLICATION

© 2019 Association of Wound, Ostomy, and Continence Nurses International | San Antonio May 7-11

Every patient presents an opportunity for learning, but sometimes a particular case is especially compelling.

Share your Most Interesting Case This Week with *Wound Management & Prevention* readers.

Send your short 3-paragraph write-up (introduction/background, care details, and prognosis/lesson learned — photos are welcome) to Barbara Zeiger, Editor of *Wound Management & Prevention* at bzeiger@hmpglobal.com.

Accepted submissions will be posted at woundmanageprevent.com.