

Improved Venous Leg Ulcer Outcomes Using a Combination of Ovine Extracellular Matrix and Gentian Violet/Methylene Blue Transfer Antibacterial Foam

Charles Andersen MD, FACS, MAPWCA; Dawn Green RN, BSN, WCC; Joan Santucci MN, RN, CWCN and Emily Phillips RN
Madigan Army Medical Center, Tacoma, WA



Introduction

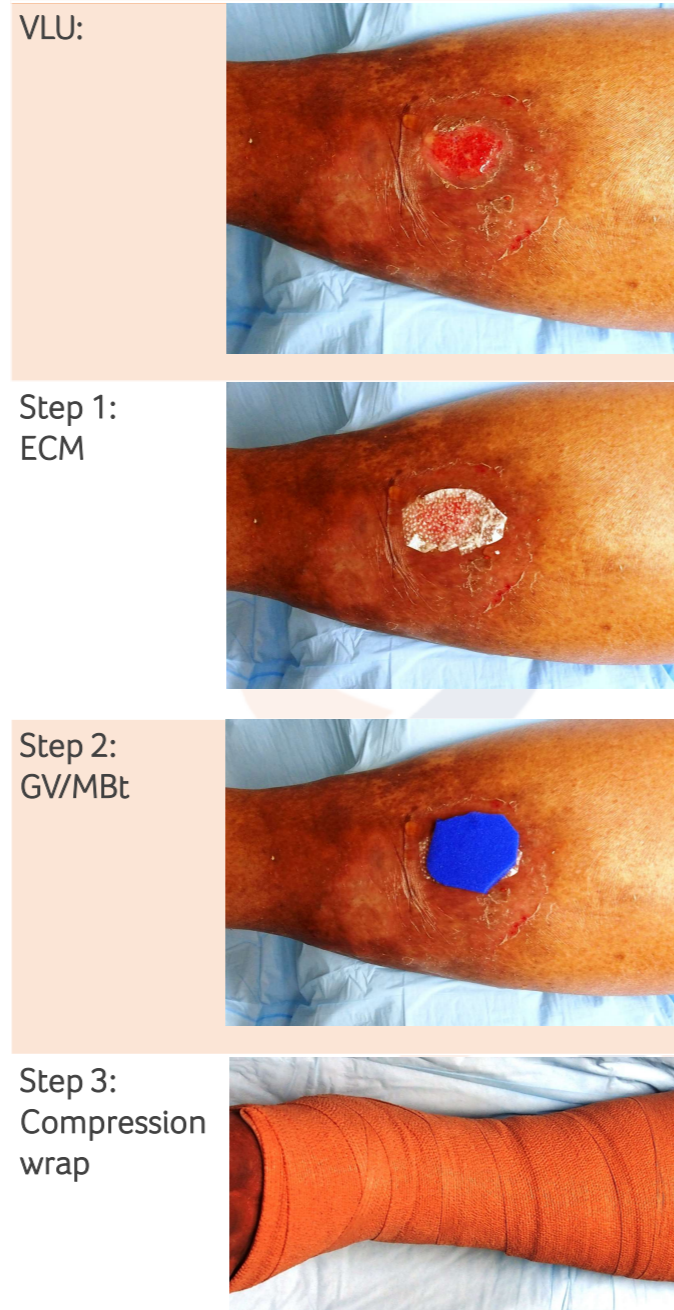
Compression therapy alone is often insufficient to heal venous leg ulcers (VLUs) within an acceptable timeframe.¹ Ovine Extracellular Matrix (ECM)⁴ and Gentian Violet/Methylene Blue transfer antibacterial foam (GV/MBt)⁵ can be effectively used under compression therapy. Also, elevated matrix-metalloproteinases (MMP) levels play a major role in the pathophysiology of VLUs, contributing to disruption or damage of the tissue.² ECM materials that provide broad spectrum MMP reduction, support granulation tissue formation and re-epithelialization may contribute to improved wound healing outcomes and shorter treatment times.³ The aim of this case series is to observe wound closure outcomes in VLUs using an ovine ECM covered by GV/MBt in conjunction with compression therapy.

Methods

In this retrospective observational case series, 10 patients with VLUs treated with ECM and GV/MBt were reviewed to determine days to wound closure. Age of patients ranged from 46-99 years old with the average age being 71 years old. Average size of wounds before treatment was 2.6 x 1.9 cm.

For treatment, ECM was cut to size and applied to the VLU and then covered with GV/MBt before the area was wrapped with a compression wrap (see Table 1, Steps 1 to 3). GV/MBt was utilized to address bioburden and moisture balance, ECM to address protease imbalance support granulation. Treatment was repeated every week or as required until closure of the wound.

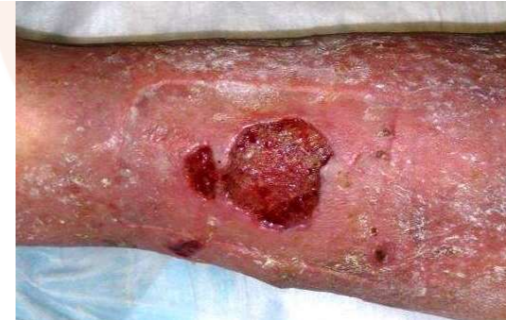Table 1. Treatment



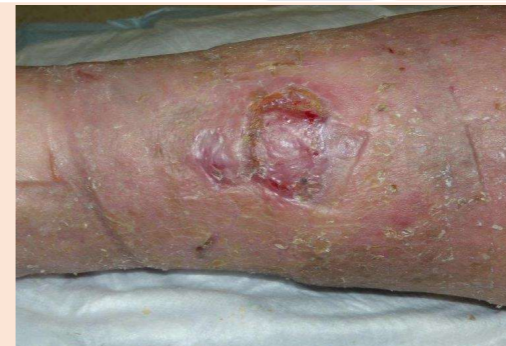Case Study 1

Patient: 85 year old male
Medical History: Chronic history of recurrent VLUs
Wound Description: Right lower extremity, 3.5 x 1 cm
Previous Treatments: Oral antibiotics and antibiotic cream

Pre-treatment
2 weeks:



Week 1:
2 x 0.5 cm.
ECM, GV/MBt,
compression
wrap.



Week 5:
Wound closed

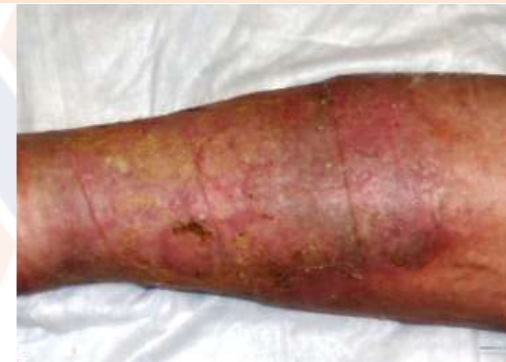

Table 2. Time to wound closure

Patient	1	2	3	4	5	6	7	8	9	10
Time (weeks)	5	3	5	3	5	12	6	4	7	7

Results

At 4 weeks the average size of the wounds (n=10) had reduced by approximately 80%. The time required for wound closure ranged between 3 to 12 weeks (see Table 2) with an average time of wound closure of 5.7 weeks.

The results demonstrated in VLU patients using compression with application of ECM to modulate proteases and using GV/MBt to manage moisture and bioburden improved healing times as compared to published literature.⁴

Conclusions

Repeated application of ECM and GV/MBt under compression for the duration of one week created overall faster wound healing times. ECM, GV/MBt and compression are a useful combination for the management of VLUs.

References and Disclosures

- Hankin CS, Knispel J, Lopes M, Bronstone A, Maus E. Clinical and cost efficacy of advanced wound care matrices for venous ulcers. *J Manag Care Pharm* 2012;18(5):375-84.
- Beidler SK, Douillet CD, Berndt DF, Keagy BA, Rich PB, Marston WA. Multiplexed analysis of matrix metalloproteinases in leg ulcer tissue of patients with chronic venous insufficiency before and after compression therapy. *Wound Repair Regen* 2008;16(5):642-8.
- Bohn G, Liden B, Schultz G, Yang Q, Gibson D. Ovine-based collagen matrix dressing: Next generation collagen dressing for wound care. *Adv. Wound Care (New Rochelle)* 2016 Jan 1;5(1):1-10.
- Margolis DJ, Berlin JA, Strom BL. Which venous leg ulcers will heal with limb compression bandages? *Am J Med.* 2000;109:15-9

Financial support was provided by Aroa Biosurgery Limited (New Zealand)

⁴Endoform Natural Dermal Template; ⁵Hydrofera Blue READY – Transfer Antibacterial Foam; www.appulsemed.com