

# OVINE FORESTOMACH MATRIX IN THE SURGICAL MANAGEMENT OF COMPLEX LOWER EXTREMITY SOFT TISSUE DEFECTS : A RETROSPECTIVE MULTI-CENTER CASE SERIES

<sup>1</sup>M. Mark Melin (MD, FACS, RPVI); <sup>2</sup>Richard Kaufman (DPM, CWSP); <sup>3</sup>James E. Geiger, Jr. (DPM, CWSP); <sup>4</sup>Brandon Bosque (DPM, CWSP)

<sup>1</sup>M Health - Fairview, Edina, MN, USA; <sup>2</sup>Piedmont Atlanta Hospital, Atlanta, GA, USA; <sup>3</sup>Northwestern Medicine, Palos Health, Palos Heights, IL, USA; <sup>4</sup>Aroa Biosurgery Limited, Auckland, New Zealand

## INTRODUCTION

Diabetic foot ulcers (DFUs) are the cause of roughly half of all nontraumatic lower limb amputations and are estimated to cost the health system \$9-13 billion per year[1]. Advanced technologies that can facilitate viable granulation tissue over exposed vital structures (i.e. bone, tendon, arteries) can shorten time to closure, reduce costs, minimize limb loss, and improve the quality of life for patients. Ovine forestomach matrix scaffold (OFM) provides over 151 native ECM proteins including collagen, elastin, glycosaminoglycans and other components that help to control the inflammatory response and support the deposition of organized new tissue[2,3]. OFM technology has been developed as a robust planar sheet or particulate variation which can be utilized in volumetric, contaminated wounds to safely cover exposed structures with viable granulation and shorten time to definitive closure.

## METHODS

All wounds required surgical management due to tissue necrosis and/or infection which resulted in significant tissue loss and exposed vital structures. Wound dimensions were recorded intra-operatively. OFM sheet and/or particulate<sup>®</sup> was hydrated with saline solution prior to application. The wounds were secured and covered with a non-adherent petrolatum dressing and secondary dressing. Negative Pressure Wound Therapy was utilized on a case-by-case basis. Wounds were assessed weekly, measured, and imaged throughout the treatment course.

## CONCLUSION

These preliminary results are part of a larger cohort currently being studied. These data support the use of OFM as a safe, cost-effective, and clinically effective treatment option to granulate over exposed vital structures and shorten time to definitive closure.

## STUDY COHORT



**53.3 cm<sup>2</sup>**  
Wound Area  
Range 4-150 cm<sup>2</sup>



**n=6/6**  
Underlying  
Osteomyelitis



**n=6/6**  
CDC Grade 4



**n=6/6**  
Exposed bone/tendon

## RESULTS



**14 days**  
Median time to  
100% granulation  
tissue



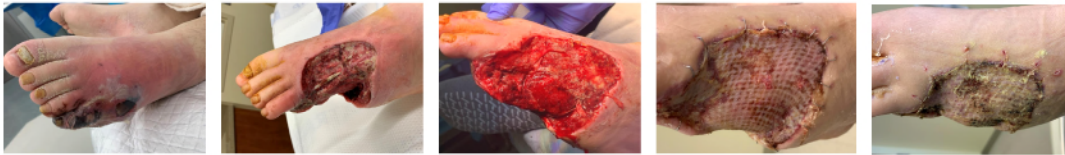**10 weeks**  
Median time  
close



**0%**  
Complication  
or Infection  
rate

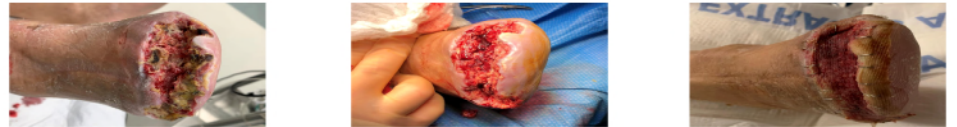### CASE 1: 28-year-old male diabetic with peripheral neuropathy, Wagner 4, necrotizing infection, fever and malaise.

Week 0: Initial Presentation      Week 0: Partial 4<sup>th</sup> and 5<sup>th</sup> ray resection, exposed tendon and bone      Week 1: 100% Granulation tissue – place STSG      Week 3: 90% STSG take      Week 5: Healed



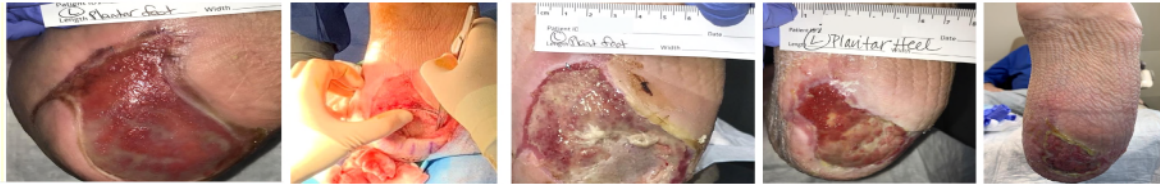
### CASE 2: 62-Year-old male diabetic with PAD, peripheral neuropathy, TMA dehiscence.

Week 0: Pre-operative status      Week 0: Sharp debridement; 7 x 4 x 2 cm; exposed bone. OFM sheet applied with NPWT      Week 1: 100% granulation tissue coverage of bone, depth filled. Ready for STSG



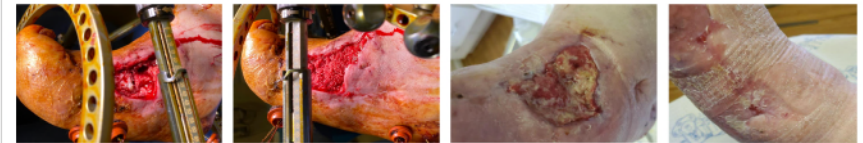### CASE 3: 58-year-old male, Wagner 3 DFU, nonhealing for 3 months, osteomyelitis, failed conservative treatment and advance treatment modalities.

Week 0: Initial Presentation      Week 0: Intra-operative application of Myriad semi-implanted into undermining, covering resected bone      Week 2: 100% granulation – no exposed bone, residual OFM noted      Week 6: Functional granulation tissue and wound contracture noted      Week 11: Continued epithelialization – limited access due to COVID 19 pandemic



### CASE 4: 52-Year-old obese male diabetic with Charcot, and peripheral neuropathy. Surgical dehisence of Charcot reconstruction.

Week 0: Sharp debridement; 7 x 6 x 5cm with exposed bone and joint.      Week 0: OFM particulate applied in void, covered with OFM sheet and NPWT      Week 6: 100% depth filled with granulation tissue. Not a candidate for STSG      Week 12: Healed by weekly OFM application



## REFERENCES AND DISCLOSURES

Product was provided by Aroa Biosurgery Limited (New Zealand), "Myriad Matrix™ and Myriad Morcells™ (Aroa Biosurgery Limited, New Zealand). 1. Centers for Disease Control and Prevention. National Diabetes Statistics Report, 2017. Atlanta, GA: Centers for Disease Control and Prevention, US Department of Health and Human Services; 2017. 2. Dempsey, S.G., et al. "Functional Insights from the Proteomic Inventory of Ovine Forestomach Matrix." J Proteome Res 18(4): 1657-1668. 3. Lun et al, 2010, "A functional extracellular matrix biomaterial derived from ovine forestomach." Biomaterials 31(16): 4517-4529.